



European Association of Urology



## Sexual Medicine

# Total Phallic Reconstruction in Female-to-Male Transsexuals

Giulio Garaffa, Nim A. Christopher, David J. Ralph\*

St. Peter's Andrology Centre and the Institute of Urology, London, UK

### Article info

#### Article history:

Accepted May 6, 2009

Published online ahead of  
print on May 19, 2009

#### Keywords:

Female to male transsexual  
Sex reassignment surgery  
Phallus  
Total phallic construction  
Phalloplasty  
Penile prosthesis

### Abstract

**Background:** The goal of total phallic construction is the creation of a sensate and cosmetically acceptable phallus. An incorporated neourethra allows the patient to void while standing, and the insertion of a penile implant allows the patient to resume sexual activities, thus improving quality of life.

**Objective:** To report our experience of total phallic construction with the use of the radial artery free flap in female-to-male transsexuals.

**Design, settings, and participants:** The notes of the 115 patients who underwent total phallic construction with the use of the radial artery-based forearm free flap between January 1998 and December 2008 were reviewed retrospectively.

**Measurements:** The surgical outcome, cosmesis of the phallus, complications, eventual need for revision surgery, and patient satisfaction were recorded during the follow-up.

**Results and limitations:** This technique allowed the reconstruction of a cosmetically acceptable phallus in 112 patients; 3 patients lost the phallus due to venous thrombosis in the immediate postoperative period. After a median follow-up of 26 mo (range: 1–270 mo), 97% of patients are fully satisfied with cosmesis and size of the phallus. Sensation of the phallus was reported by 86% of patients. Urethral strictures and fistulae in the phallus and join-up site were the most common complications, occurring respectively in 9 and 20 patients; however, after revision surgery, 99% of patients were able to void from the tip of the phallus while standing.

**Conclusions:** The radial artery-based forearm free flap technique is excellent for total phallic construction, providing excellent cosmetic and functional results.

© 2009 European Association of Urology. Published by Elsevier B.V. All rights reserved.

\* Corresponding author. 145 Harley Street, W1G 6BJ London, UK. Tel. +44 207 486 3805.  
E-mail address: [dralph@andrology.co.uk](mailto:dralph@andrology.co.uk) (D.J. Ralph).

## 1. Introduction

Gender reassignment surgery for the female-to-male transsexual (FTMT) involves subcutaneous mastectomy, hysterectomy, salpingo-oophorectomy, vaginectomy, total phallic construction, and placement of penile and testicular prostheses. The main goals of surgery are the creation of a cosmetically acceptable sensate phallus with the

incorporation of a neourethra to allow voiding in a urinal and with enough bulk to allow the insertion of a penile prosthesis for sexual intercourse [1].

The classic method of penile reconstruction involves the use of abdominal flaps. The first total phallic construction was attempted in 1936 by Bogoras [2], who used a random pedicled oblique abdominal singular tube with no incorporated neourethra. Phallic rigidity was obtained by inserting rib cartilage inside the flap.

Maltz [3] and Gillies and Harrison [4] subsequently improved the Bogoras technique by creating a phallus which incorporated a neourethra using the *tube within a tube* concept. These procedures were multistaged, resulted in extensive scarring and disfigurement of the donor area, and produced a phallus with no sensation.

Further advances involved the use of infraumbilical skin and groin flaps [5–10]. The main limitation of these techniques was the formation of an insensate and wedge-shaped phallus. Musculocutaneous thigh flaps, used when there was extensive abdominal scarring from previous surgery or radiotherapy, have also been abandoned due to poor results [11–16].

With the advent of microsurgical techniques, a new era has started for total phallic construction. Originally described in 1982 by Song et al [17], the use of the radial artery free flap phalloplasty was first published in 1984 by Chang and Hwang [16], who used this technique successfully for total phallic reconstruction in seven patients who had previously had a penile amputation. The reconstructive procedure involved the creation of a tube within a tube using forearm skin, with the urethra fashioned from the non-hair-bearing area, and the whole flap was based on the radial artery.

After the success of this series, many teams adopted this technique and applied some modifications in flap design to improve the cosmesis of the neophallus and to minimise the overall complication rate and donor-site morbidity that can occur in 45% of cases [18]. Particularly, the shape of the forearm flap has been modified to improve the blood supply to the flap and to reduce the risk of meatal stenosis [19–24]. Ulnar artery-based flaps have also been used to reduce the amount of hair-bearing skin that is incorporated [25].

## 2. Patients and methods

The notes of 115 FTMT patients who had undergone total phallic construction using the radial artery-based forearm free flap were reviewed. The median age at surgery was 34.9 yr (range: 20–55 yr).

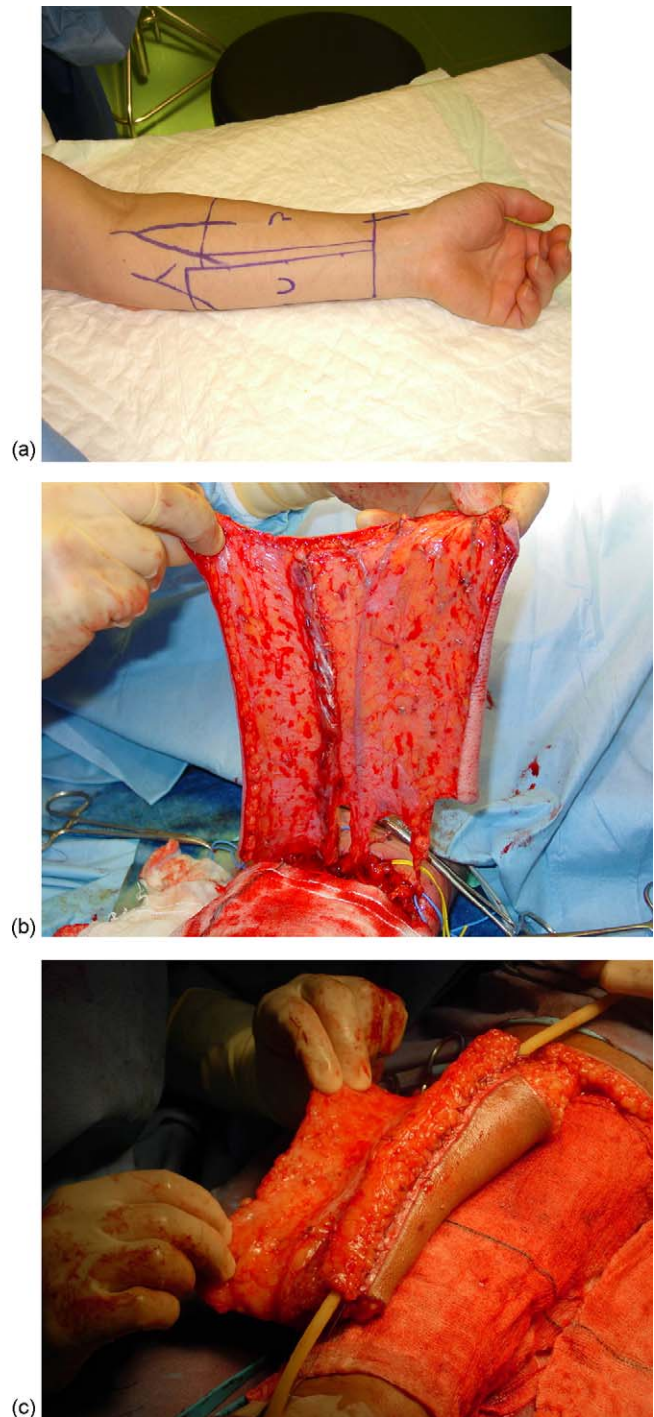
The subordinate forearm was used in all patients. The vascular competency of the superficial and deep palmar arteries was checked with an Allen test, followed by duplex ultrasonography when in doubt.

The total phallic construction was done using a modified Chang and Hwang flap [16]. The process of total phallic construction involved the following stages: 1) creation of the phallus with a competent neourethra and microvascular transfer to the recipient site, 2) anastomosis of the native urethra to the phallic urethra with the use of local labial flaps, 3) sculpture of the glans according to the Norfolk technique [15] and insertion of one testicular prosthesis in one of the labia, and 4) insertion of a penile implant into the phallus. Usually, hysterectomy and bilateral salpingo-oophorectomy are performed at stage 1, a vaginectomy is offered to patients at stage 2 or 3, and the reservoir of a three-piece inflatable penile implant can be inserted at stage 3.

Each stage was done at 3-mo intervals, with complications of one stage being dealt with during the following stage to reduce the overall number of operations.

### 2.1. Stage 1

The general dimension of the flap varied according to the size of the donor forearm and at the patient's request. On average, a 4 × 17-cm strip from the hairless medial aspect of the forearm was used for the



**Fig. 1 – The radial artery-based forearm free flap: (a) the 4 × 17-cm strip is located on the relatively less hairy ulnar aspect of the forearm; (b) the flap is raised on its pedicle; (c) the flap is tubularised around a 16-Ch Foley catheter.**

neourethra. This strip was tubularised over a 16-F catheter and spatulated at the proximal end. The phallic part was generally 13–14 cm long and was wrapped around the urethra in a tube-within-a-tube fashion (Fig. 1).

The flap is based on the radial artery, which is dissected to its origin with the brachial artery. The venous drainage was based on the cephalic vein, other flap veins, and venae comitantes of the radial artery. The

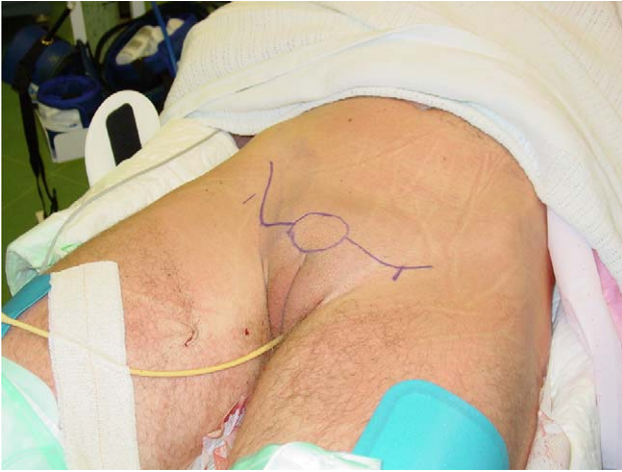

Fig. 2 – The recipient site.

sensation of the flap was provided by the medial and lateral cutaneous nerves of the forearm. The flap was raised with tourniquet compression of a maximum of 2 h of inflation time.

The phallus was then transposed to the recipient area (Fig. 2), and the following vascular, neural, and urethral microsurgical anastomoses were made (Fig. 3):

- Arterial: radial to inferior epigastric artery
- Venous: cephalic to long saphenous; usually the radial venae comitantes are incorporated with the cephalic:
  - Other flap veins to other saphenous or branches
  - Radial venae comitantes to inferior epigastric comitantes, if not with cephalic
- Neural: cutaneous nerves to ilioinguinal, iliohypogastric, or dorsal clitoral.

Anastomotic variations were tailored according to the number of and access to veins and nerves. A median of three venous (range of one to five) and two neural (range of one to four) anastomoses were made. The

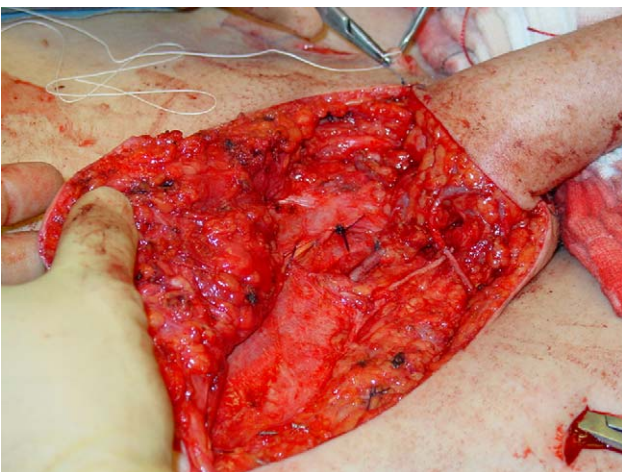


Fig. 3 – The microsurgical anastomoses are completed in 8-0 nylon sutures. In the centre of the field the anastomosis between radial and inferior epigastric artery is evident. The venous anastomosis between a flap vein and a branch of the right long saphenous vein and a neural anastomosis between a cutaneous nerve of the flap and ilioinguinal nerve are visible in the right side of the field.

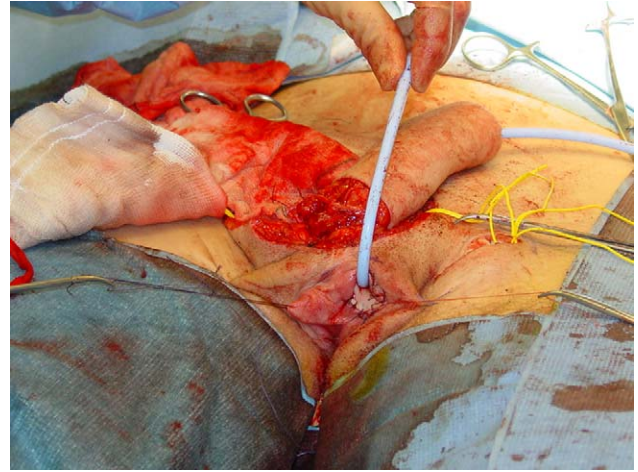


Fig. 4 – The proximal end of the spatulated neourethra is sutured to a U-shaped flap of inner labial skin, lateral to the clitoris, for a subsequent anastomosis to the native urethra.

proximal end of the spatulated neourethra was sutured to a U-shaped flap of inner labial skin, lateral to the clitoris, for a subsequent anastomosis to the native urethra (Fig. 4). The neourethra was primarily anastomosed in two patients who had previously undergone metoidioplasty.

The defect on the donor forearm was covered with a full-thickness skin graft (FTSG) harvested from the patient's buttock in 75 cases, from the abdomen in 37 cases, and from the axilla in 1 case (Fig. 5). A split-thickness skin graft (STSG) harvested from the thigh was used in two patients. A compression dressing was then applied to the graft, and the arm was elevated for 1 wk. The arm was inspected weekly thereafter.

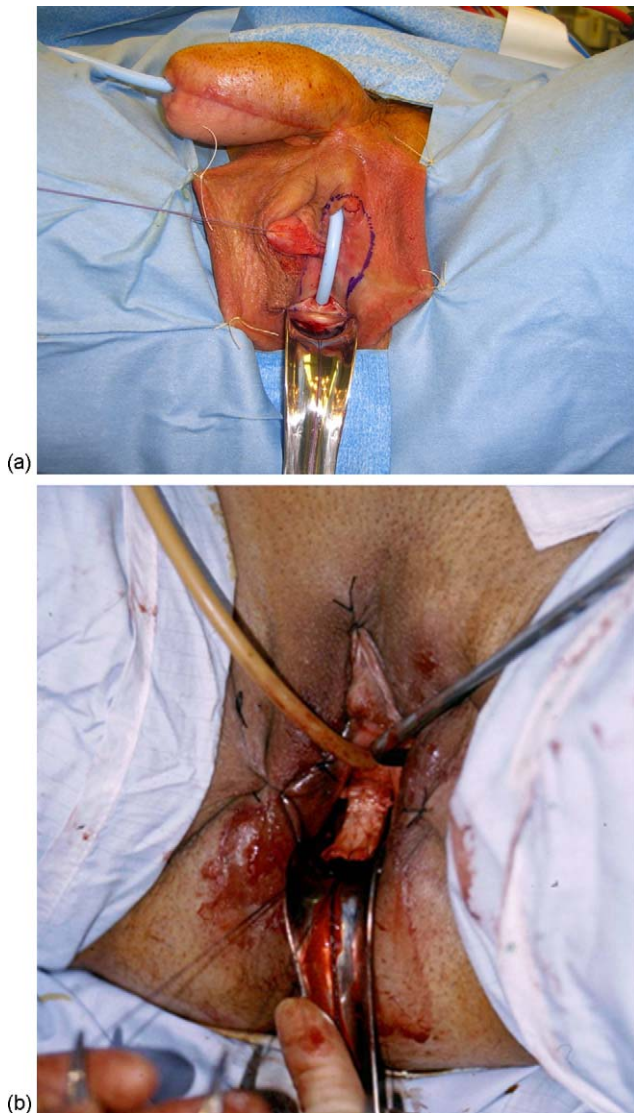
## 2.2. Stage 2

Approximately 3 mo after phallic construction, the proximal end of the neo-urethra was anastomosed to the native urethra with the use of local labial and anterior vaginal flaps (Fig. 6a).

An anterior vaginal flap of approximately 2 × 2 cm was harvested and rotated forward to be included in the dorsal aspect of the urethra (Fig. 6b). This change ensured that no suture line appeared in the midline

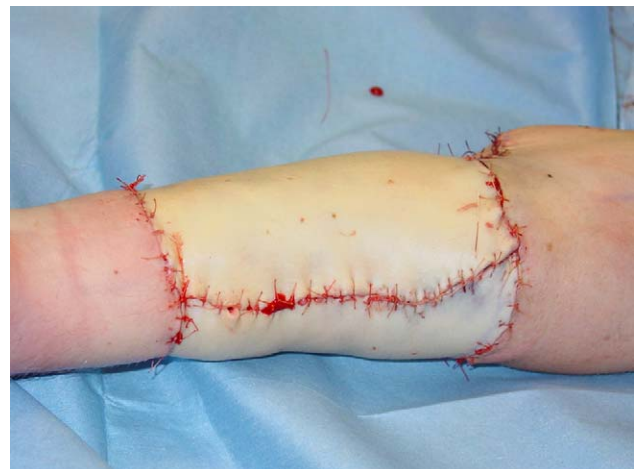

Fig. 5 – A full-thickness skin graft is used to cover the defect on the donor arm.

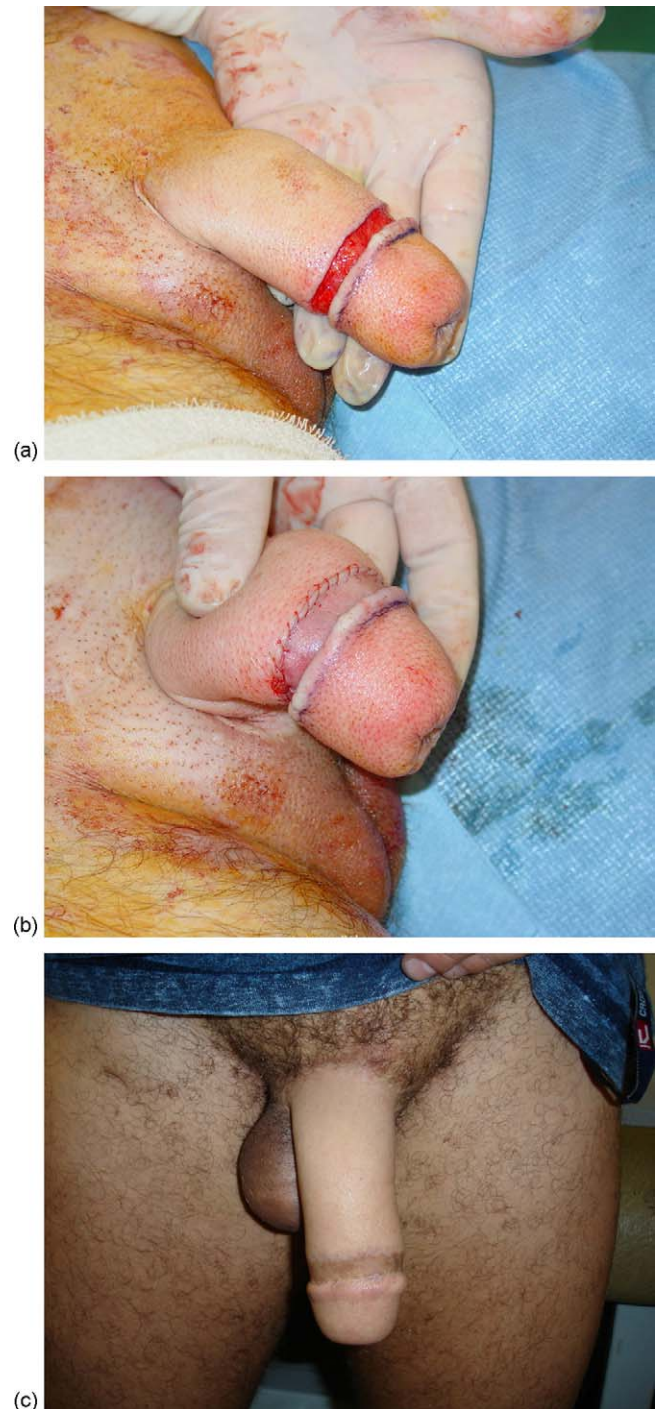


**Fig. 6** – The native urethra is joined with the phallic urethra with the use of labial and vaginal flaps: (a) To reduce the risk of fistula formation, a Martius fat flap is raised from one of the labia majora and is rotated to cover the anastomosis; (b) a 2 × 2-cm anterior vaginal flap is harvested and rotated forwards to be included in the dorsal aspect of the urethra.

at the neonative urethral junction and, thus, should have reduced subsequent fistula formation, which can be as high as 75% if this change is not done [26].

A Martius fat flap covered the anastomosis to further reduce the risk of fistula formation. Urethral and suprapubic catheters were inserted during the procedure. The urethral catheter was usually removed 1 wk postoperatively, with the suprapubic catheter clamped at 3 wk postoperatively and then removed once the patient was able to void comfortably from the neophallus in the absence of strictures and fistulae.

Patients were given an option with regards to the management of the clitoris. An option was leaving the clitoris on the exterior for those wishing to continue manipulating it for sexual pleasure; alternatively, the glans of the clitoris would be de-epithelialised and then hidden under the skin. The scrotum was fashioned by excision of the hairless inner labial skin and labia minora and with direct apposition of both labia majora on the midline. To elevate the scrotum, a V-Y plasty was



**Fig. 7** – (a) A circumferential incision is carried out around the phallus to simulate a normal coronal sulcus and the skin is lifted and rolled up to form a corona; (b) a full-thickness skin graft is inserted in the defect; (c) the final result.

performed at the lower extremity of the labia on both sides to give the scrotum a more rounded appearance (Fig. 7c).

### 2.3. Stage 3

A glans was then fashioned using the Norfolk technique [15]. The phallus was incised circumferentially and obliquely to simulate a normal coronal

sulcus, the skin was lifted and rolled up to form a corona, and then an FTSG was inserted into the defect (Fig. 7). This work was performed at a separate stage because it is a full-thickness distal skin incision that, with the delayed operation, would potentially reduce the vascular risk to the rolled-up flap, as the phallus has been allowed to gain extra vascularity. An abdominal skin incision was made to harvest the graft, so it was often convenient at this stage to insert the reservoir component of the penile implant with direct vision into the extraperitoneal space. The reservoir was filled, and the tubing was capped off with a deactivation plug. On the same side, a single large testicular prosthesis was inserted into the labia majora/neoscrotum together with the reservoir tubing. Any complications from stages 1 and 2 were also corrected during this stage, if possible.

#### 2.4. Stage 4

This stage involved the insertion of one or two cylinders and the pump of an inflatable penile prosthesis (AMS CX 700; American Medical Systems, Milwaukee, MN, USA) and will be discussed in a future paper.

An assessment of the surgical outcome included the ability to stand and void without the symptoms of a urethral stricture or fistula. This ability is one of the main goals in phalloplasty surgery. Cystoscopic review of the neourethra was not performed and uroflow studies were not performed because there were no nomograms to compare within this group of patients. All complications and revision surgery were documented.

Patients' satisfaction and tactile sensation were assessed subjectively by direct questioning of the patients in a prospective manner. Sensation was a prerequisite for penile prosthesis insertion.

### 3. Results

After a median follow-up of 26 mo (range: 1–270 mo), 67 patients had completed stage 3, 17 had completed stage 2, and 31 had phallus construction only.

Overall, 83 of the 84 patients (99%) who had urethral continuity were able to void from the tip of the phallus in a standing position. One patient developed an anastomotic stricture that will require further surgical management.

Complete phallus sensation was reported in 82 patients (71.5%); of the remainder, 17 patients (14.7%) reported sensation only within the neourethra, 7 (6.0%) had an insensate phallus, 6 (5.2%) had recent surgery and were too early to assess, and 3 (2.6%) had phalluses that were lost. The last 10 patients had clitoral nerve anastomosis but they are not sexually active, so erogenous sensation has not been assessed in them yet.

All patients with a surviving phallus were fully satisfied with the size and cosmesis of the neophallus and declared in a telephone interview that they would advise an FTMT friend to undergo the same procedure for total phallic construction.

All complications of stage 1 are reported in Table 1, although one complication usually resulted in the development of a secondary urethral complication.

Of the early complications, acute arterial thrombosis occurred in two cases that presented within the first 24 h after surgery and was characterised by a pale and cold phallus that had lost its pulse. This complication was successfully managed with an immediate reexploration of

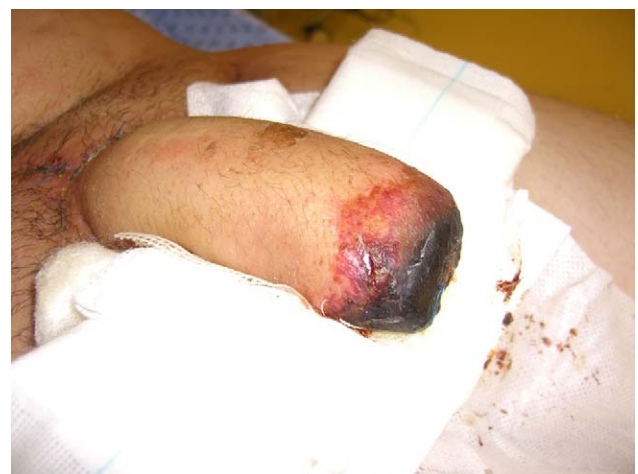**Table 1 – Complications of phallus construction in 115 patients**

Complication	No. of patients	%
Acute arterial thrombosis	2	1.7
Acute venous thrombosis	3	2.6
Phallus loss	3	2.6
Partial skin necrosis	12	10.4
Infection	5	4.3
Contracture	4	3.4
Meatal stenosis with or without fistulas	9	7.8

the anastomosis and Fogarty catheter thrombectomy. Acute venous thrombosis occurred in three patients, two within the first 48 h and one at 2 wk. This complication was characterised by a progressive engorgement of the phallus that appeared oozy and discoloured and with a progressive weakening of the pulse due to the progressive venous congestion and compression. Despite an immediate attempt of reexploration, the microcirculation could not be restored; therefore, the phallus was removed.

In 12 patients, partial necrosis of the flap occurred at the proximal and distal third of the ventral aspect, the areas that are least vascularised (Fig. 8). In three patients, a debridement of the necrotic tissue with advancement of a labial flap to cover the defect was performed. In the remainder, the defect was minor and it was left to heal by second intention. Minor wound infections occurred in five patients and were always managed successfully with the administration of broad-spectrum antibiotics.

The phallus contracted along the ventral suture line in four patients; three of those had experienced partial necrosis of the phallus. Scar revision with split-skin grafting was necessary in all patients. A meatal stricture occurred in nine patients, usually as a consequence of phallus infection or necrosis, and was associated with the development of a urethral fistula. This complication was dealt with by a two-stage buccal graft meatoplasty with closure of any fistulae.



**Fig. 8 – Partial necrosis involving the tip and the distal third of the ventral aspect of the phallus. The complication was managed with debridement of the necrotic tissue, once it was well demarcated from the surrounding healthy-looking tissue. The defect was then left to heal by second intention.**

**Table 2 – Complications and management of urethroplasty (stage 2) in 84 patients**

Complication	No. of patients (%)	Management	No. of patients managed	Recurrence of complication
Haematoma	2 (2.4)	–	–	0
Strictures	9 (10.7)	Drainage	2	0
		Buccal/labial graft urethroplasty	5	0
Fistula	20 (23.8)	Anastomotic urethroplasty	3*	7
		Fistula excision	20	–

\* One patient has not been treated yet.

The graft take on the arm was incomplete in seven patients and resulted in a degree of contraction that required surgical excision of the tethered area followed by repair with an STSG. A permanent but minimal loss of motility occurred in 2 patients and a minor loss of sensation over the anatomical *snuff box* (radial fossa) was reported by 10 patients. One patient developed a compartment syndrome of the hand, which resulted in a contraction deformity. Minor lymphoedema of the hand that does not interfere with hand mobility was reported by two patients.

The complications of stage 2 are reported in Table 2. As mentioned previously, one complication usually resulted in the development of a secondary urethral complication.

Wound haematomas at the level of the join-up site were the only early complication. They occurred in two patients and were managed with drainage and administration of broad-spectrum antibiotics. Both patients then developed a urethral fistula.

An anastomotic stricture of the neonative urethra occurred in nine patients, and a fistula developed proximally to the stricture in all of these cases. Overall, 20 patients developed a urethral fistula.

The management of the stricture consisted of a one- or two-stage buccal or labial graft urethroplasty in five patients and an anastomotic urethroplasty in three patients; one patient has not been treated yet and voids through a suprapubic catheter. The urethral fistulae were closed by excision of the fistulae and closure in layers with advanced labial flaps. A revision fistula closure was necessary in seven patients.

So far, no patient has had hair incrustation in the neourethra, although a cystoscopic examination is not routinely performed.

The glans sculpture gave excellent cosmetic results in all patients except in two cases that were characterised by a poor graft take.

#### 4. Discussion

Since its original description by Song et al [17] and Chang and Hwang [16], penile reconstruction using the radial artery-based forearm free flap has proven to be superior to all other techniques. It guarantees a superior cosmetic result by forming a cylindrical phallus rather than the wedge-shaped infraumbilical and groin flap phalloplasty [5–10] and is less prone to postoperative contracture than

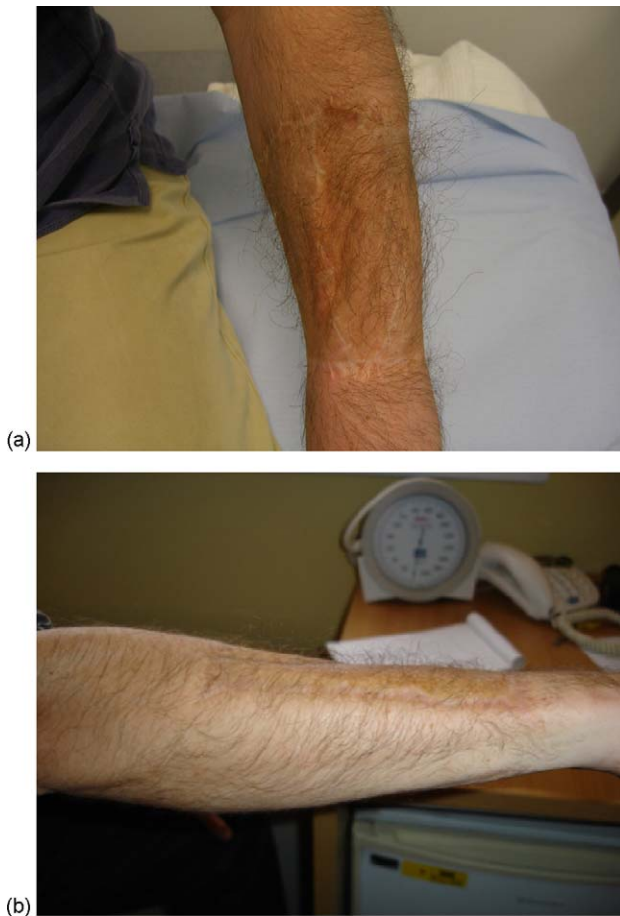
musculocutaneous flaps [11–16]. It allows the creation of a neourethra that reaches the tip of the phallus, which is less prone to complications. Urethral complications with other types of phalloplasty occur in up to 65% of cases and often require multiple revisions [26]. A neourethra can be also be fashioned by inserting a tubularised radial artery-based forearm free flap inside an abdominal phalloplasty, as described by Dabering et al [22], which yields excellent functional results with low complication rates but at the expense of an additional stage. It also allows the creation of a sensate phallus, whereas in other phalloplasties, the sensation in minimal [26].

As in all major phalloplasty surgery, complication rates are high, as was the case in the present series. These results are similar to the ones presented by Monstrey et al, who, in a series of 81 patients, reported a 19% rate of thrombosis of the microvascular anastomosis with fistulas and stricture rates respectively of 21% and 32% [27].

Loss of skin on the phallus can be a problem, particularly if the phalloplasty is large and stretches the capacity of the vascular supply to reach the edges. This complication occurred in 12 patients and necessitated revision. One complication, however, often leads to another, and urethral strictures with associated fistulae resulted from this complication. But all of the urethral complications can be overcome and are less common than in other types of phalloplasty. Particularly in metoidioplasty and labial urethroplasty, the urethral complication rate can reach 88% and 75%, respectively [26,28].

One drawback of the present technique is the donor-site morbidity. This problem can be dramatically reduced by adequate preparation of the donor site for grafting [29]. This preparation involves adequate haemostasis, the advancement of the edges of the intact forearm skin to reduce the area that requires grafting, and minimisation of the step between normal skin and the muscle bed for creating a flat surface on which to place the skin graft. As to the covering of the defect, FTSGs have been better than split skin, due to a lower rate of scarring and contracture and to superior cosmesis (Fig. 9).

Despite the eventual donor-site morbidity, the necessity of multiple surgical stages, and the high complication rates, all patients were highly satisfied with the outcome of a functionally and cosmetically acceptable phallus. The results of this series concur with others in that the microsurgical radial artery-based forearm free flap phalloplasty technique consistently provides the patient with an excellent result [27,30].



**Fig. 9 – (a, b) The final result of the donor arm after grafting with a FTSG. This excellent cosmetic result demonstrates how adequate preparation of the forearm for grafting can dramatically reduce morbidity at the donor site.**

## 5. Conclusions

This series shows that the radial artery–based forearm free flap represents the gold standard technique for total phallic construction. It provides superior cosmetic and functional results and guarantees the highest satisfaction rates among patients.

**Author contributions:** David J. Ralph had full access to all the data in the study and takes responsibility for the integrity of the data and the accuracy of the data analysis.

**Study concept and design:** Garaffa, Ralph, Christopher.

**Acquisition of data:** Garaffa.

**Analysis and interpretation of data:** Garaffa.

**Drafting of the manuscript:** Garaffa, Ralph, Christopher.

**Critical revision of the manuscript for important intellectual content:** Ralph, Christopher.

**Statistical analysis:** Garaffa.

**Obtaining funding:** None.

**Administrative, technical, or material support:** Ralph.

**Supervision:** Ralph.

**Other (specify):** None.

**Financial disclosures:** I certify that all conflicts of interest, including specific financial interests and relationships and affiliations relevant to the subject matter or materials discussed in the manuscript (eg, employment/affiliation, grants or funding, consultancies, honoraria, stock ownership or options, expert testimony, royalties, or patents filed, received, or pending), are the following: None.

**Funding/Support and role of the sponsor:** None.

## References

- [1] Hage JJ, Bloem JJAM, Suliman HM. Review of the literature on techniques for the phalloplasty with emphasis on the applicability in female-to-male transsexuals. *J Urol* 1993;150:1093–8.
- [2] Bogoras N. Über die volle plastische wiederherstellung eines zum Koitus fähigen Penis (penioplastica totalis). *Zentralbl Chir* 1936;63:1271–6.
- [3] Maltz M. Maltz reparative technique for the penis. In: Maltz M, editor. *Evolution of Plastic Surgery*. New York, NY: Froben Press; 1946. p. 278–9.
- [4] Gillies HD, Harrison RJ. Congenital absence of the penis with embryological consideration. *Br J Plast Surg* 1948;1:8–28.
- [5] Laub DR, Laub II DR, Hentz VR. Penis construction in female to male transsexuals. In: Eicher W, Kubli F, Herms V, editors. *Plastic Surgery in the Sexually Handicapped*. New York, NY: Springer Verlag; 1989 p. 113–28.
- [6] Snyder CC, Browne Jr EZ. Intersex problems and hermaphroditism. In: Converse M, editor. *Reconstructive Plastic Surgery. Principles and Procedures for Correction, Reconstruction and Transplantation*. 2nd ed. Philadelphia, PA: W. B. Saunders Co.; 1977 . p. 3941–9.
- [7] Bouman FG. The first step in phalloplasty in female transsexuals. *Plast Reconstr Surg* 1987;79:662–4.
- [8] McGregor IA, Jackson IT. The groin flap. *Br J Plast Surg* 1972; 25:3–16.
- [9] Puckett CL, Montie JE. Construction of male genitalia in the transsexual, using a tubed groin flap for the penis and a hydraulic inflation device. *Plast Reconstr Surg* 1978;61:523–30.
- [10] Perovic S. Phalloplasty in children and adolescents using the extended pedicle island groin flap. *J Urol* 1995;154:848–53.
- [11] Hotchkiss RS, Morales PA, O'Connor Jr JJ. Plastic reconstructive surgery after total loss of the penis. *Am J Surg* 1956;92:403–8.
- [12] Julian R, Klein MH, Hubbard H. Management of thermal burn with amputation with amputation and reconstruction of the penis. *J Urol* 1969;101:580–6.
- [13] Kaplan I. A rapid method for constructing a functional sensitive penis. *Br J Plast Surg* 1971;24:342–4.
- [14] Orticochea M. A new method of total reconstruction of the penis. *Br J Plast Surg* 1972;25:347–66.
- [15] Persky L, Resnick M, Desprez J. Penile reconstruction with gracilis pedicled grafts. *J Urol* 1983;129:603–5.
- [16] Chang TS, Hwang WY. Forearm flap in one-stage reconstruction of the penis. *Plast Reconstr Surg* 1984;74:251–8.
- [17] Song R, Gao Y, Song Y, Yu Y, Song Y. The forearm flap. *Clin Plast Surg* 1982;9:21–6.
- [18] Fang RH, Kao YS, Ma S, Lin JT. Phalloplasty in female-to-male transsexuals using free radial osteocutaneous flap. A series of 22 cases. *Br J Plast Surg* 1999;52:217–22.
- [19] Gilbert DA, Jordan GJ, Devine CJ, Winslow BH. Microsurgical forearm ‘cricket bat-transformer’ phalloplasty. *Plast Reconstr Surg* 1992;4:711–6.
- [20] Semple JL, Boyd JB, Farrow GA, Robinette MA. The ‘cricket bat flap’: a one-stage free forearm flap phalloplasty. *Plast Reconstr Surg* 1991;88:514–9.

- 
- [21] Gilbert DA, Schlossberg SM, Jordan GH. Ulnar forearm phallic reconstruction and penile reconstruction. *Microsurgery* 1995;16: 314–21.
- [22] Dabernig J, Shelley OP, Cuccia G, Schaff J. Urethral reconstruction using the forearm free flap: experience in oncologic cases and gender reassignment. *Eur Urol* 2007;52:547–54.
- [23] Hoebeke PB, Rottey S, Van Heddeghem N, et al. One-stage penectomy and phalloplasty for epithelioid sarcoma of the penis in an adolescent. *Eur Urol* 2007;51:1429–32.
- [24] Hoebeke PB, Rottey S, Van Heddeghem N, et al. One-stage penectomy and phalloplasty for epithelioid sarcoma of the penis in an adolescent: part 2. *Eur Urol* 2007;51:1744–7.
- [25] Gottlieb LJ, Levine LA. A new design for the radial forearm free-flap phallic construction. *Plast Reconstr Surg* 1992;92:276–83.
- [26] Bettocchi C, Ralph DJ, Pryor JP. Pedicled pubic phalloplasty in females with gender dysphoria. *BJU Int* 2005;95:120–4.
- [27] Monstrey S, Hoebeke P, Dhont M, et al. Radial forearm phalloplasty: a review of 81 cases. *Eur J Plast Surg* 2005;28: 206–12.
- [28] Sohn M, Bosinski HAG. Gender identity disorders. diagnostic and surgical aspects. *J Sex Med* 2007;4:1193–208.
- [29] Selvaggi G, Monstrey S, Hoebeke P, et al. Donor-site morbidity of the radial forearm free flap after 125 phalloplasties in gender identity disorder. *Plast Reconstr Surg* 2006;118:1171–7.
- [30] Hage JJ, Bouman FG, De Graaf FH, Bloem JJA. Construction of the neophallus in female-to-male transsexuals: the Amsterdam experience. *J Urol* 1993;149:1463–8.